

S. Ricciardi<sup>1</sup>, D. Vogelaers<sup>2</sup>,  
F. Van Wanzele<sup>2</sup>, I. Colle<sup>3</sup>,  
H. Van Vlierberghe<sup>3</sup>, B. de Hemptinne<sup>1</sup>,  
R. Troisi<sup>1</sup>

## Specific Problems in a HIV Positive Patient with End-Stage Alcoholic Liver Disease after Liver Transplantation: Infections and Immunosuppression

We report a 54-year-old man with decompensated alcoholic liver cirrhosis and HIV infection who underwent liver transplantation (LTx). Due to relatively well preserved cellular immunity until 2003, no antiretroviral therapy (HAART) needed to be instituted. However, deterioration of his clinical state indicated the need for LTx. At that time, the viral load was of 4.84 Log and the CD4 count was more than 250 cells/mm<sup>3</sup>. The post transplant course was complicated by several infection episodes and one episode of acute cellular rejection grade 2. HAART consisted of lamivudine, stavudine, lopinavir and ritonavir. One week after start of HAART, TAC were discontinued during 18 days due to ritonavir interaction and successively modified switching ritonavir to nevirapine. CD3/CD4 T-helper lymphocyte count showed a significant decrease immediately after LTx which rapidly recovered after initiation of HAART. The patient was discharged on the 8<sup>th</sup> postoperative week in good conditions and he is doing very well 1-year following LTx. This report encourages the institution of HAART once the liver graft regains normal function. Drug interactions between ritonavir and tacrolimus should be anticipated. A study protocol to manage these patients within a multidisciplinary team including also specialists in infectious diseases and virologists is mandatory.

### Key words:

HIV infection, solid organ transplantation, liver transplantation

### **Besondere Probleme bei einem HIV-positiven Patienten mit terminaler alkoholbedingter Lebererkrankung nach Lebertransplantation: Infektionen und Immunsuppression**

*Wir berichten über einen 54 Jahre alten Mann mit dekompenzierter alkoholbedingter Leberzirrhose und einer HIV-Infektion, bei dem eine Lebertransplantation (LTx) durchgeführt wurde. Aufgrund der relativ gut erhaltenen Zellimmunität bis zum Jahr 2003 war bis dahin keine antiretrovirale Therapie (HAART) erforderlich. Die Verschlechterung seines klinischen Zustandes machte jedoch eine LTx erforderlich. Zu dieser Zeit betrug die Virusbelastung ca. 4.84 Log und die CD4-Zahl lag bei über 250 Zellen/mm<sup>3</sup>. Die Verlauf nach LTx wurde durch verschiedene Infektionen sowie eine akute zelluläre Abstoßungsepisode Grad 2 beeinträchtigt. Die HAART setzte sich zusammen aus Lamivudin, Stavudin, Lopinavir*

<sup>1</sup>Dept. of General, Hepato-Biliary and Transplantation Surgery; <sup>2</sup>Dept. of Internal Medicine; <sup>3</sup>Dept. of Hepato-Gastroenterology, Ghent University Hospital Medical School, Ghent, Belgium

*und Ritonavir. Eine Woche nach Beginn der HAART wurde TAC für 18 Tage aufgrund von Wechselwirkungen mit Ritonavir ausgesetzt und von Ritonavir allmählich zu Nevirapin gewechselt. Die CD3/CD4-T-Helfer-Lymphozytenzahl zeigte einen signifikanten Rückgang unmittelbar nach der LTx mit rascher Erholung nach Beginn der HAART. Der Patient wurde in der 8. postoperativen Woche in gutem Allgemeinzustand entlassen, und es geht ihm 1 Jahr nach LTx sehr gut. Dieser Bericht spricht für den Beginn einer HAART, sobald das Lebertransplantat seine normale Funktion aufgenommen hat. Mit Wechselwirkungen zwischen Ritonavir und Tacrolimus muss gerechnet werden. Zur Betreuung dieser Patienten ist daher ein Studienprotokoll im Rahmen eines multidisziplinären Teams mit Spezialisten für Infektionskrankheiten und Virologen zwingend erforderlich*

### **Schlüsselwörter:**

*HIV-Infektion, Organtransplantation, Lebertransplantation*

## **Introduction**

AIDS-related morbidity and mortality in human immunodeficiency virus (HIV)-infected patients continue to decrease as a result of highly active anti-retroviral therapy (HAART) and prophylaxis for traditional opportunistic infections. While first results of solid organ transplantation in HIV-infected recipients were dismal, with the introduction of HAART therapy organ transplants in HIV-infected recipients are currently feasible under specific conditions (1, 3). Patients with HIV often have hepatitis C virus (HCV) or hepatitis B (HBV) co-infection. Due to better HIV disease control with HAART therapy, the morbidity rates from these end-stage liver diseases (ESLD) leading to cirrhosis within this population are increasing (1). Recently, increased mortality from end-stage liver disease rather than AIDS-associated opportunistic infections and neoplasm has been recorded (2). Due to better HIV outcome but dismal prognosis of end-stage liver disease, liver transplantation (LTx) is not contraindicated any more in selected HIV-positive recipients suffering from ESLD. Furthermore, choice and dosing of antiretroviral agents would have been hampered by concerns of hepatotoxicity and poor liver function, prior to liver transplantation. We discuss the specific problems in a HIV positive patient with end-stage alco-

holic liver disease after liver transplantation.

## **Case Report**

A 54-year-old man, suffering from decompensated alcoholic liver cirrhosis, underwent liver transplantation in April 2003 at the Ghent University Hospital. HIV infection was diagnosed in 1993. In 1999 an oral carcinoma in situ was resected. In the same year alcoholic liver cirrhosis with portal hypertension was diagnosed. At that time, serology for both HBV and HCV were negative. Due to relatively well preserved cellular immunity from diagnosis to 2003, no HAART therapy needed to be instituted.

Due to the deterioration of his clinical state at the beginning of 2003 (jaundice and ascites decompensation – MELD score 22 – HIV-1-RNA), the patient was considered for LTx. At that time, the viral load was of 4.84 Log (Amplacor-Roche) and the CD4 count was more than 250 cells per cubic millimeter ( $\approx 300/\mu\text{L}$ ) with a mean ratio CD4/CD8 of 0.22 (normal values 1.0-3.6). Pre-transplant work-up revealed no absolute contraindications for LTx and the patient was put on the waiting list with the aim to start HAART therapy after LTx when the liver function recovered. In April 2003 he underwent a standard LTx from a brain-dead donor. The basic immunosuppressive

regimen consisted out of tacrolimus (TAC) in monotherapy (Fig.1). The post transplant course was complicated by acute renal failure related to contrast CT and tacrolimus administration.

A perforation of the distal esophagus due to post-resection ischemia occurred one week after LTx and made a revision laparotomy necessary. A positive blood culture with coagulase negative Staphylococcus occurred thereafter and was treated by teicoplanin (post operative day [POD] 8). Successively, a wound fluid, infected with *Aspergillus fumigatus* was recorded on POD 16 and treated with ambisome (dose: 3 mg/Kg). The patient experienced one episode of acute cellular rejection grade II responding to pulse steroid therapy on POD 6. HAART was instituted 4 weeks postoperatively and consisted of lamivudine (150 mg x2), stavudine (30 mg x 2), lopinavir and ritonavir (3 c x2). One week after start of the antiretroviral therapy, TAC through levels increased up to 74 ng/mL due to an interaction between TAC and ritonavir. TAC was discontinued during 18 days because of toxic plasma levels. HAART regimen was successively modified switching ritonavir to nevirapine (200 mg x 3) (fig.1). The TAC was reintroduced to achieve a trough target level of about 10 ng/mL just before HAART switching. However, due to increased serum creatinine levels the daily dose of FK was reduced and the immunosuppressive regimen was changed by associating mycophenolate mofetil. CD3/CD4 T-helper lymphocyte count showed a significant decrease immediately after LTx which rapidly recovered after initiation of HAART reaching a threshold value of 200/ $\mu\text{L}$  after 6 months. (Fig. 2). The patient was discharged on the 8<sup>th</sup> postoperative week in good conditions. One year following LTx the patient is doing very well with normal liver chemistry and no signs of infections. His basic immunosuppressive regimen consisted of 5 mg daily TAC achieving mean through levels of 5.3 $\mu\text{g}/\text{dl}$  and mycophenolate mofetil (2 x 500 gr). His CD4 count at this moment was 347 / $\mu\text{L}$  with repetitive undetectable viral load.

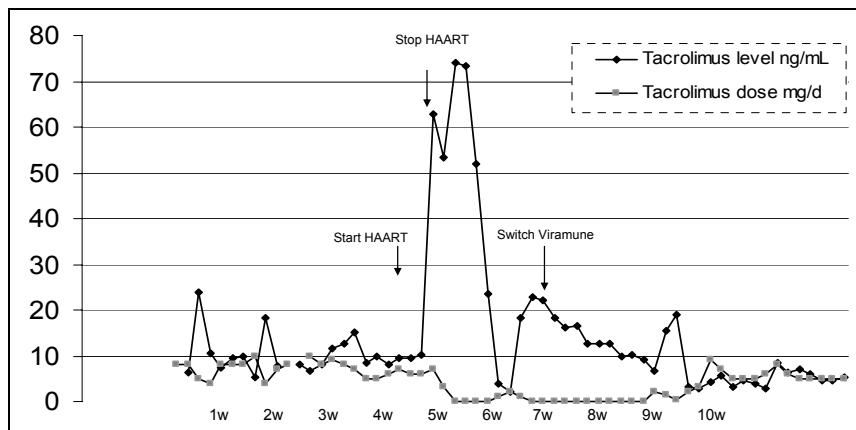


Fig. 1: Tacrolimus doses and trough levels.

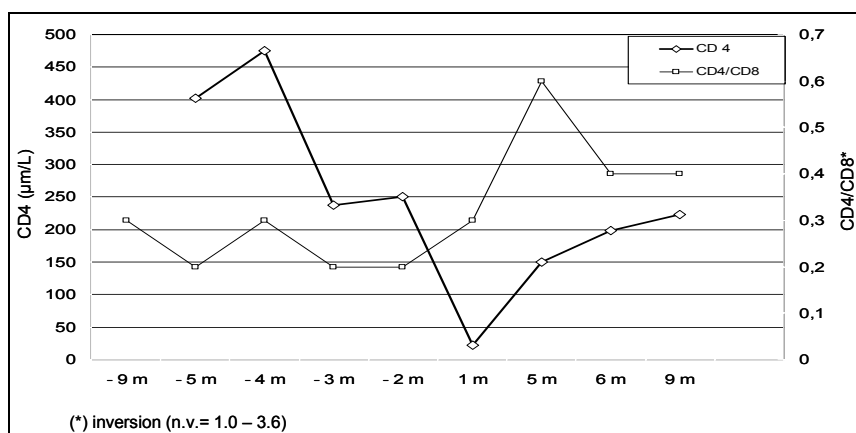


Fig. 2: Evolution of CD4 and CD4/CD8 ratio levels before and after OLT.

## Discussion

LTx is an accepted therapy for a wide variety of end-stage liver diseases. HIV-infected patients have been generally excluded due to poor results in the pre-HAART era. Early reports suggested that the course of HIV infection was accelerated in transplant patients, either because of the effect of immunosuppression and the role of alloantigenic stimulation in HIV replication. The underlying cause of end-stage liver disease such as HCV infection may increase overall morbidity. In HIV/HCV coinfecting patients, the rate of hepatic fibrosis is accelerated with more rapid progression to cirrhosis. A CD4 count of <200 cells per cubic millimeter is an independent factor for accelerated fibrosis in co-infected patients. Interferon and ribavirin may be safe and well tolerated in the context of antiretroviral therapy (4). However, lactic acidosis has been described in patients on HAART treated with ribavirin (5). The clinical course of chronic hepatitis B

does not seem to be significantly altered by HIV co-infection.

When the patient's status accords to the normal selection criteria (alcohol free for more than 6 months, functional level, employment, family history) alcoholic end-stage liver cirrhosis and HIV co-infection could be considered as an indication for liver transplantation. The clinical availability of HAART combining at least 2 nucleoside analogues with protease inhibitors or non nucleoside reverse transcriptase inhibitors has proven its efficacy against opportunistic infections and tumors, reducing both hospitalization and mortality rates. The introduction of HAART in untreated individuals is commonly associated with an increase in CD4 cells, together with a rapid decline of the HIV plasma viral load (6, 7).

Toxicity of antiretroviral therapy is a major point in the treatment of transplant patients as well as its interaction with the standard immunosuppressive regimens (8). The most common effects

described are: gastrointestinal intolerance and lipid abnormalities with long-term lipodystrophy, bone marrow toxicity and mitochondrial damage (neuropathy/myopathy), skin rash, and inhibition of cytochrome P450 (drug interactions). Patients with advanced AIDS or with detectable viral load after HAART therapy (multiple drug resistance) are not good candidates for liver transplantation at this time. Advanced liver failure requiring life support such as dialysis or mechanical ventilation may also preclude a liver transplantation. However, if LTx can be done without excessive risks, the HAART may be instituted once the liver regains normal function. The inclusion criteria include a CD4 cell count greater than 200/ $\mu$ L, an undetectable HIV viral load under therapy, and the absence of AIDS-defining conditions. Interactions between ritonavir and tacrolimus (by CYP3A4 inhibition) should be anticipated resulting in very low weekly doses (i.e. 1 mg) and predisposing to secondary renal insufficiency. Switch to nevirapine may solve this interaction ensuring adequate antiviral protection (9, 10). The early outcome of liver transplantation in HIV-positive patients in this new era is improved and one should not exclude a potential candidate from transplantation when the short term prognosis is negatively affected by liver disease. Single center experience and organ pool resources are the major factors limiting the transplantation of HIV positive patients. In this setting, liver transplantation for alcoholic liver disease may be performed with lower morbidity and, probably, a better outcome than HCV-coinfecting recipients. Introduction of HAART is convenient after recuperation of the liver function following LTx but drug interactions between ritonavir and tacrolimus should be anticipated. A study protocol to manage these patients within a multidisciplinary team including also specialists in infectious diseases and virologists is mandatory.

## References

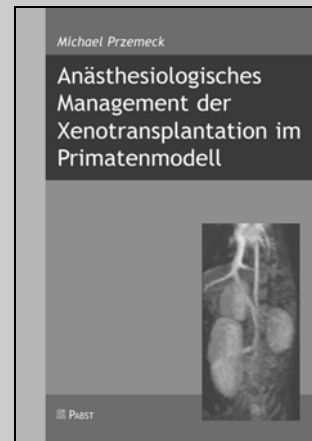1. Neff GW, Bonham A, Tzakis AG et al. (2003) Orthotopic liver transplantations in patients with human immunodeficiency virus and end-stage liver disease. *Liver Transplant* 9 (3): 239-247

2. Kuo PC (2001) Reconsideration of HIV as a contraindication to transplantation. *Transplantation* 71 (11): 1689
3. Prachalias AA, Pozniak A, Taylor C, Muiesan P, Heaton ND et al. (2001) Liver Transplantation in adults coinfectd with HIV. *Transplantation* 72: 1684-1688
4. Tzakis A, Cooper MH, Dummer JS, Ragni M, Ward JW, Starzl TE (1990) Transplantation in HIV positive patients. *Transplantation* 49: 354-8
5. Carr A (2003) Lactic Acidemia in Infection with Human Immunodeficiency Virus. *Clinical Infectious Diseases* 36 (Suppl 2): S96-100
6. Gow PJ, Pillay D, Mutimer D (2001) Solid organ transplantation in patients with HIV infection. *Transplantation* 72 (2): 177-181
7. Samuel D, Valee J-CD, Teicher E, Vittecoq D (2003) Liver Transplantation in patients with HIV infection. *Journal of Hepatology* 39: 3-6
8. Jain AKB, Fung J et al. (2002) The interaction between antiretroviral agents and tacrolimus in liver and kidney transplant. *Liver Transplant* 8 (9)
9. Jain AB, Venketeramanan R, Eghtesad B, Marcos A, Fung JJ et al. (2003) Effect of coadministered lopinavir and ritonavir (Kaletra) on tacrolimus blood concentration in liver transplantation patients. *Liver Transplant* 9 (9): 954-960
10. Schonder KS, Shullo MA, Okusanya O (2003) Tacrolimus and lopinavir/ritonavir interaction in liver transplantation. *Ann Pharmacother* 37 (12): 1793-96

Salvatore Ricciardi, M.D.  
Dept. of General, Hepato-Biliary and  
Transplantation Surgery  
Ghent University Hospital  
Medical School  
2 K12 IC  
De Pintelaan 185  
B-9000 Ghent  
Belgium  
E-mail: Salvatore.Ricciardi@ugent.be

Michael Przemek

## Anästhesiologisches Management der Xenotransplantation im Primatenmodell



Stünde die Xenotransplantation, die Übertragung von Zellen, Gewebe oder Organen über Speziesgrenzen hinweg, als klinisch etablierte Technik zur Verfügung, böte sich eine einzigartige Perspektive, dem weltweit herrschenden und sich ständig verschärfenden Mangel an geeigneten Spenderorganen zu begegnen. Ungeachtet der bedeutenden ethischen und sozialen Bedenken stehen der klinischen Anwendung der Xenotransplantation jedoch operative, infektiologische und immunologische Probleme entgegen, die bislang nur partiell gelöst sind und daher weitergehender Forschung bedürfen. Wegen der phylogenetischen Nähe zum Menschen werden für diese tierexperimentellen Untersuchungen oft Primaten verwendet. Über die anästhesiologische und intensivmedizinische Behandlung der Organempfänger während und nach der Operation und über ihren Einfluß auf das Transplantationsergebnis gibt es bislang keine umfassenden Untersuchungen.

Dieses Buch stellt das an der Medizinischen Hochschule Hannover entwickelte Konzept zum perioperativen Management der porcinen Xeno-Nieren- bzw. -Lungentransplantation auf Javaner-Affen dar. Ein besonderer Fokus liegt dabei auf dem kardiovaskulären System der Organempfänger. Dieses ist durch die bei der Reperfusion der xenogenen Organe typischerweise äußerst heftig einsetzende immunologische Abwehrreaktion besonders belastet. Mit Hilfe der transpulmonalen Thermodilutionstechnik, die bei den Lungentransplantationen durch die Pulskonturanalyse ergänzt wird, gelingt ein detailliertes kardiovaskuläres Monitoring und es wird eine präzise Steuerung des Kreislaufsystems möglich. Hierdurch können Transplantatfunktion und Überlebensrate der Empfängertiere in der frühen postoperativen Phase deutlich verbessert werden.

**88 Seiten, ISBN 3-89967-204-6, Preis: 12,- Euro**

Pabst Science Publishers  
Eichengrund 28, D-49525 Lengerich, Tel. ++ 49 (0) 5484-308,  
Fax ++ 49 (0) 5484-550, E-mail: pabst.publishers@t-online.de  
Internet: www.pabst-publishers.de